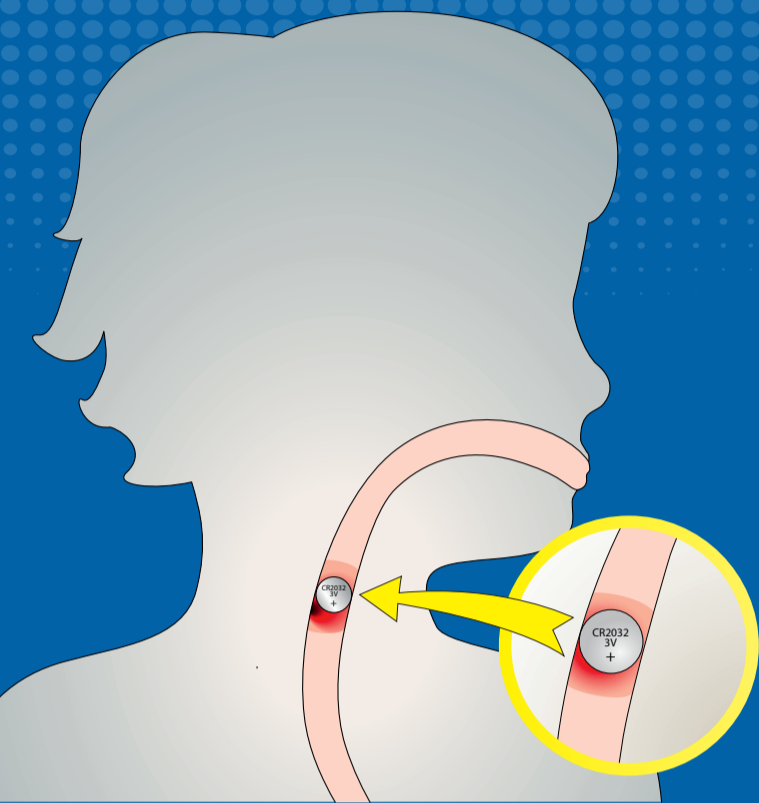




# BATTERY SWALLOWED? → FOLLOW THESE STEPS




**1**   
Time to act!  
→ do not wait  
for symptoms




  
**<12h**  
(>1 year) after swallows to  
bridge waiting time give  
2tbs honey every 10min up  
to 6x


**2**   
Immediate  
endoscopic  
removal


**<12h**   
**Diagnosis**  
X-ray thorax, neck & abdomen in 2  
levels in case of prolonged history/  
suspicion of esophageal lesion that  
has already occurred >12h consider  
CT prior to endoscopic removal

**SYMPTOMS:**  
Airway obstruction or wheezing,  
drooling, vomiting, chest  
discomfort, difficulty swallowing,  
decreased appetite, refusal to  
eat, coughing, choking

**3**   
Asses  
risk factors for  
bleeding

  
Prepare for **instability**

**4**   
Inpatient  
monitoring

  
Consider 50–150ml  
**0.25% acetic acid irrigation**  
post-removal if no signs of  
perforations/fistulations

**<6 YEARS  
HIGH-RISK  
PATIENT**

