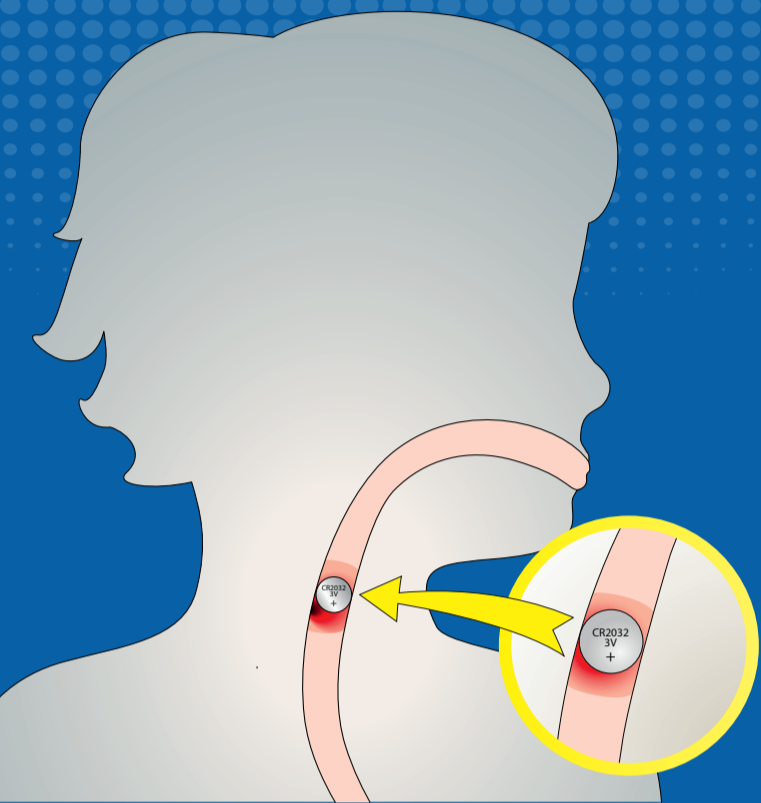


BATTERY SWALLOWED? → FOLLOW THESE STEPS



SYMPTOMS:

Airway obstruction or wheezing, drooling, vomiting, chest discomfort, difficulty swallowing, decreased appetite, refusal to eat, coughing, choking

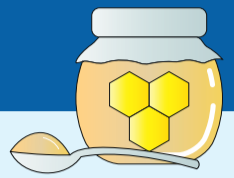**<6 YEARS
HIGH-RISK
PATIENT**

1 **<2h**
Time to act!
→ do not wait for symptoms



<12h

(>1 year) after swallow to bridge waiting time give 2tsp honey every 10min up to 6x




2
Immediate endoscopic removal

<12h

Diagnosis

X-ray thorax, neck & abdomen in 2 levels in case of prolonged history/suspicion of esophageal lesion that has already occurred >12h consider CT prior to endoscopic removal

3
Asses risk factors for bleeding



Prepare for **instability**

4
Inpatient monitoring



Consider 50–150ml **0.25% acetic acid irrigation** post-removal if no signs of perforations/fistulations

